



PRESENTING CLINICAL SIGNS

History: History of elevated BNP (2305). Two previous echos WNL. Receiving thyro tabs. Sedated for exam with acepromazine and butorphanol.

DATE

9/27/21

ECHOCARDIOGRAPHIC FINDINGS

2D, M-mode, and Doppler study. This exam is compared to the one performed 3/1-/21.

PERFORMED BY:

Left atrial size is normal. The mitral valve appears normal, though trace mitral regurgitation is present. Left ventricular dimensions are normal, as is left ventricular systolic function. The aorta and aortic valve are normal. Right atrial and right ventricular dimensions are normal. The tricuspid valve appears normal, though trivial tricuspid regurgitation is present. The pulmonary artery and pulmonic valve appear normal, though trivial pulmonic insufficiency is present. No pericardial effusion or cardiac masses are seen.

Dr. Brian Barnes

INTERPRETED BY

Keith Blass, DVM,
MS, DACVIM
(Cardiology)

ECG during echo: Sinus arrhythmia

PATIENT

Stella Brach

LA - 39.0 mm (prev. 40.1 mm)
LVIDd - 39.3 mm (prev. 39.4 mm)
LVIDs - 26.8 mm (prev. 24.7 mm)
FS - 31.8% (prev. 37.3%)
LVOT - 1.51 m/s (prev. 1.48 m/s)
RVOT - 1.15 m/s (prev. 0.90 m/s)

SPECIES

Canine

ASSESSMENT/RECOMMENDATIONS

Normal echocardiogram

BREED

Golden Retriever

This examination again demonstrates no evidence of structural heart disease. As such, no reason for Stella's previously elevated BNP level is appreciated in the image set, and, as mentioned previously, it's likely that the elevation is a false positive or secondary to a non-cardiac abnormality.

No therapy is recommended based on this exam.

SEX

A recheck echocardiogram is recommended if new physical exam and/or clinical abnormalities suggestive of cardiac dysfunction develop.

FS

AGE

10 y

WEIGHT

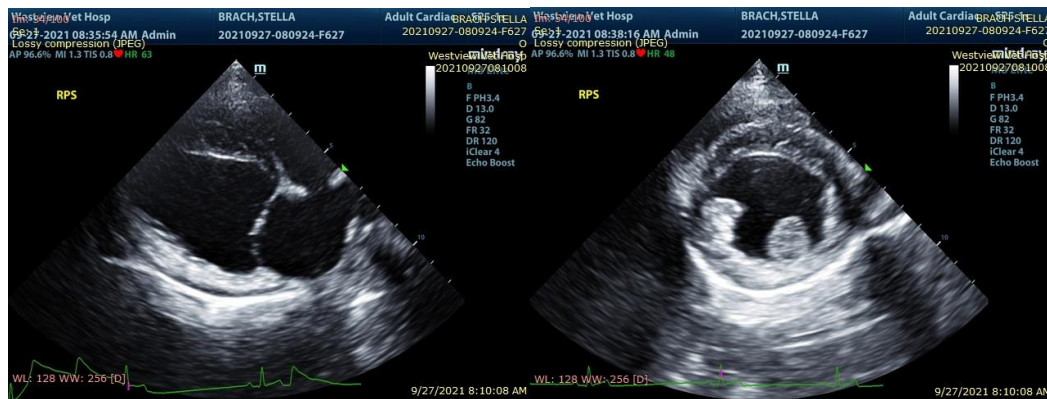
33.05 kg

HOSPITAL NAME

Westview VH

REFERRING VET

Dr. Barnes



The information and recommendations provided are based on the images presented by the referring veterinarian. No evaluation can be communicated regarding pathology that was not



visible in the image/video clips provided.

DATE

Thank you for this referral. If the clinical or image interpretation does not parallel your findings or if I can be of any further assistance please contact me.

9/27/21

PERFORMED BY:

Keith Blass, DVM, MS, DACVIM (Cardiology)
KeithBlass@gmail.com
631-804-5754

Dr. Brian Barnes

INTERPRETED BY

Keith Blass, DVM,
MS, DACVIM
(Cardiology)

PATIENT

Stella Brach

SPECIES

Canine

BREED

Golden Retriever

SEX

FS

AGE

10 y

WEIGHT

33.05 kg

HOSPITAL NAME

Westview VH

REFERRING VET

Dr. Barnes